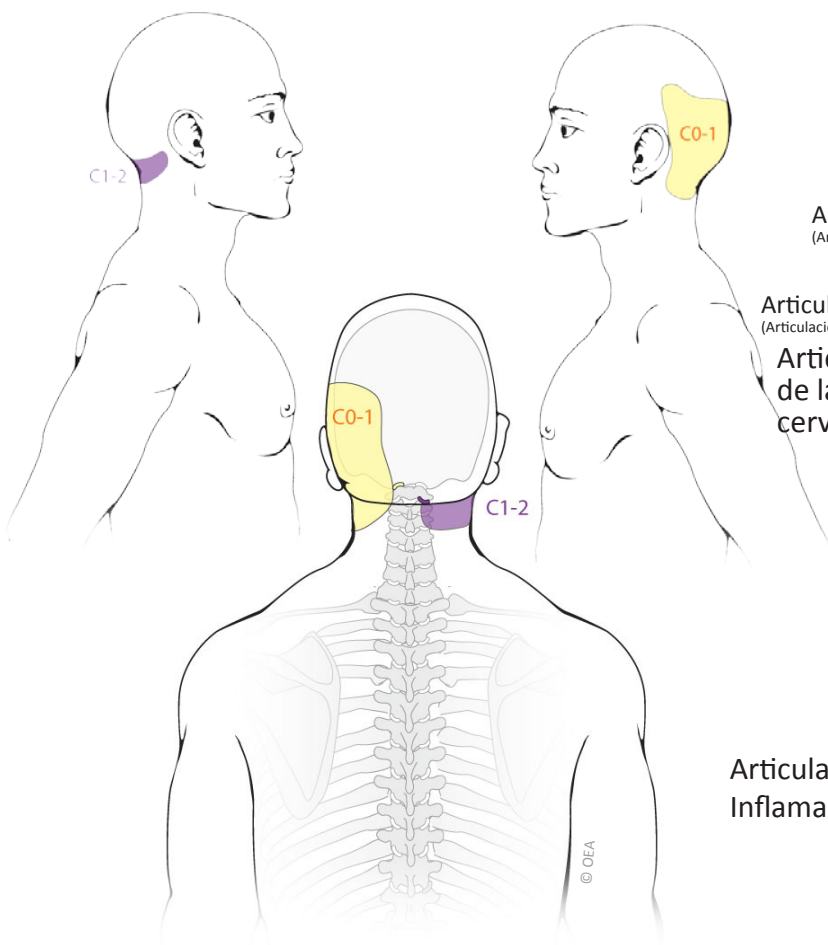
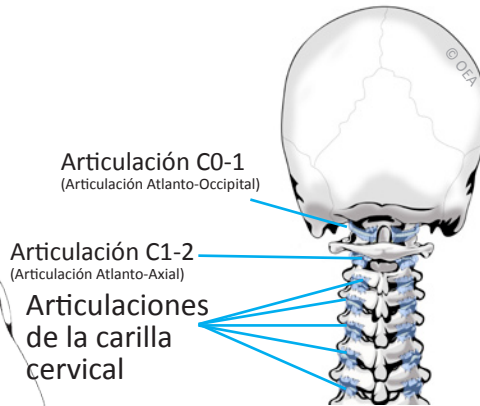


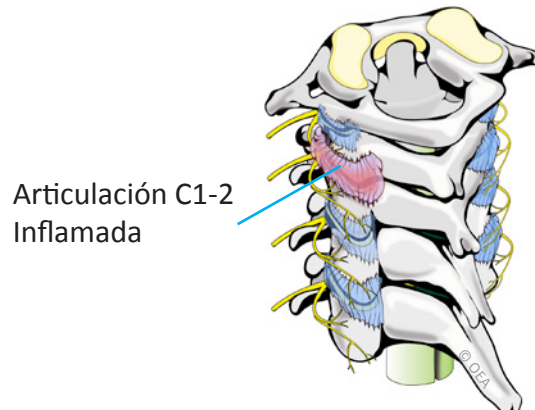
Patrones de Dolor Articular en C0-1 y C1-2



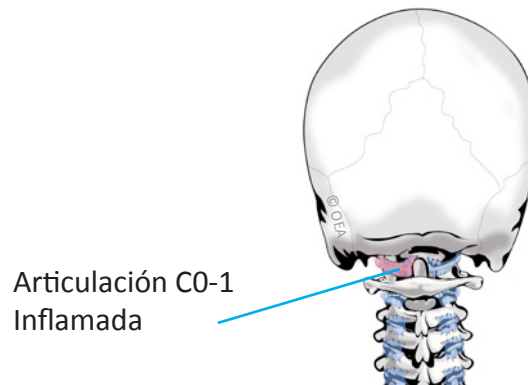
Normal Anatomy



Sinovitis C1-2



Sinovitis C0-1



Based on: Dreyfuss P, Michaelsen M, Fletcher D. Atlanto-occipital and lateral atlanto-axial joint pain patterns. *Spine*. 1994; 19(10):1125-31.



Eduardo E. Anguizola, MD & Hooman Rastegar, MD
Pain Management

714-543-2554