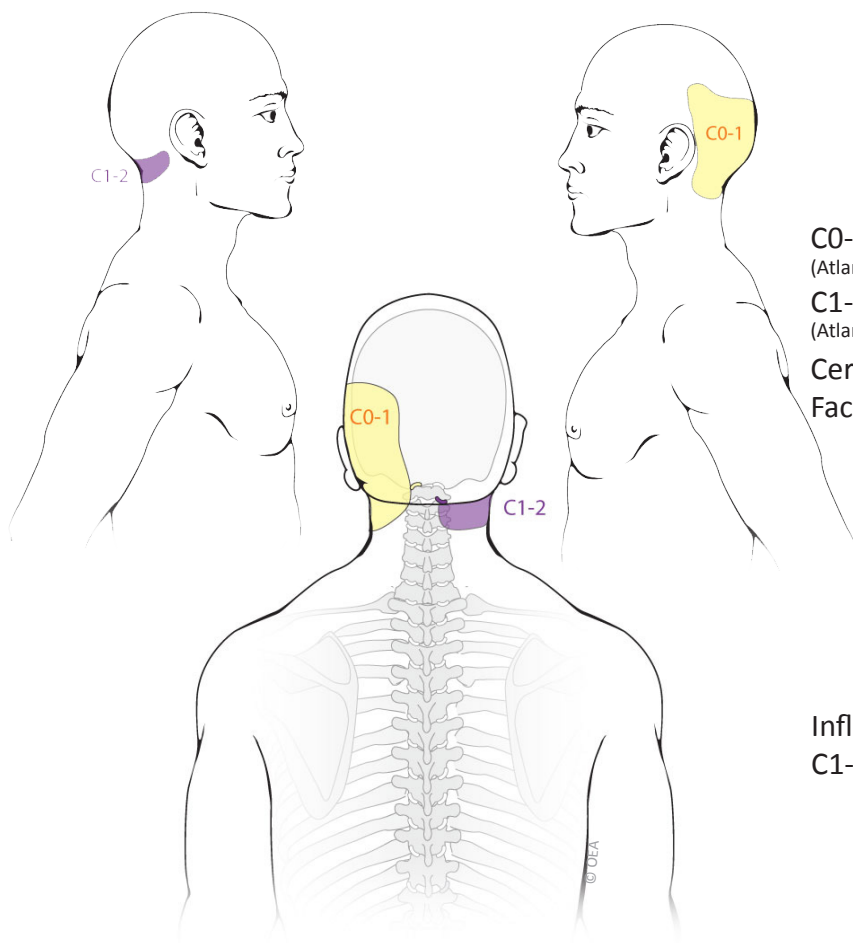
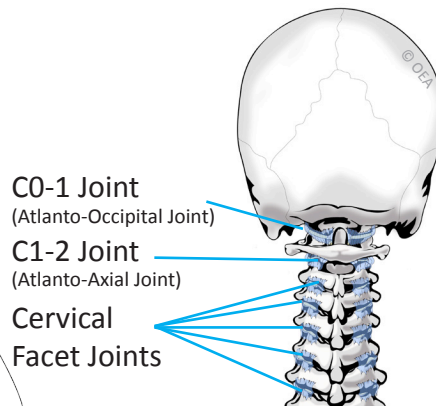


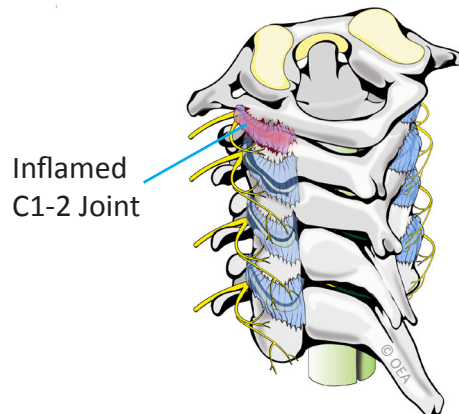
C0-1 and C1-2 Joint Pain Patterns



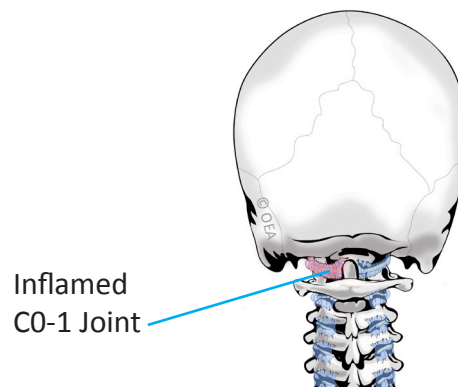
Normal Anatomy



C1-2 Synovitis



C0-1 Synovitis



Based on: Dreyfuss P, Michaelsen M, Fletcher D. Atlanto-occipital and lateral atlanto-axial joint pain patterns. *Spine*. 1994; 19(10):1125-31.



Eduardo E. Anguizola, MD & Hooman Rastegar, MD
Pain Management

714-543-2554